

A COMPARISON OF IMAGING MODALITIES TO MONITOR THERMAL AND MECHANICAL ULTRASOUND TISSUE THERAPIES

Arthur Worthington, Sankar Narasimhan, Jahan Tavakkoli, and Michael C. Kolios
Department of Physics, Ryerson University, Toronto, Canada mkolios@ryerson.ca

1. INTRODUCTION

High-intensity ultrasound can be used to produce localized tissue destruction. For long enough pulses, cytotoxic effects are thermal in origin. For higher intensities, shorter pulses, cytotoxic effects result from mechanical tissue destruction (also known as histotripsy). For these modalities to gain clinical acceptance, a noninvasive real-time monitoring technique is required to assess the tissue damage. In this work, conventional ultrasound imaging, transmission ultrasound imaging and photoacoustic imaging are compared as to their ability to discriminate lesions created by high intensity therapeutic ultrasound, resulting in both thermally and mechanically induced tissue destruction.

2. METHOD

2.1 High Intensity Focused Ultrasound

High intensity focused ultrasound (HIFU) was used to create thermal lesions by coagulating the target tissue. A 1MHz, F#0.8, and 125mm aperture diameter transducer (Imasonic, Besançon, France) was used to deliver the therapeutic ultrasound energy. Derived from computer simulations and verified by measurements, the full width at half maximum (FWHM) lateral and axial dimensions of the focal spot in water are estimated as 1.7mm and 6.8mm respectively. A SONIX RP® clinical imaging system (Ultrasonix Medical Corp., Richmond BC, Canada) was used to monitor lesion growth in real time pre-, during and post-exposure via its endocavity 6MHz convex array probe which was coaxially mounted in the centre of the therapy transducer. An AFG3101 arbitrary function generator (Tektronix Inc., Beaverton, OR) provided the bursts of RF to an AG1012 RF power amplifier (T&C Power Conversions Inc., Rochester, NY) which drove the therapeutic transducer. A typical HIFU exposure was 30 s of 200W (electric) delivered in bursts of 1000 cycles every 2 ms. Given the 60% efficiency measured by the manufacturer and the estimated FWHM dimensions, this leads to a spatial peak pulse average intensity (I_{SPPA}) of 5286 W/cm² and peak acoustic pressure (P_{max}) of 12.6 MPa at the focus in water. After the exposures, the tissue sample was also imaged using an ultrasound transmission camera (AcoustoCam®, Imperium Inc. Rockville, MD) and a photoacoustic Small Animal Imager (Imagio®, Seno Medical Instruments, Inc.). The Imagio® uses a Nd:YAG laser to emit 6ns, 50mW, 1064nm pulses to produce thermoelastic expansion in the target tissue. This expansion produces ultrasound pressure signals which are received by a 4 element annular array ultrasound transducer centered at frequency of 4.5MHz. After all the imaging techniques had

been tried, the tissue was cut open so that lesions could be measured and photographed.

2.2 Histotripsy

The same transducer system was used to create histotripsy lesions: short bursts with high peak negative pressure fragmented the target tissue without raising the temperature. A typical exposure was 3 or 4 minutes of 500W (electric) delivered in bursts of 15 cycles at a PRF of 100 Hz. This corresponds to $I_{SPPA}=13215$ W/cm², and $P_{max}=19.7$ MPa at the focus. The exposure was monitored in real time via the B- and Power Doppler modes of the Ultrasonix® scanner. The lesions were monitored post exposure using the imaging systems described in Section 2.1.

3. RESULTS

3.1 Coaxial mounted transducer array

The coaxially mounted transducer array, running in B-mode, clearly showed HIFU lesions forming in real time during and after the exposure. Some of the backscattered signal was due to the thermal coagulation of the tissue and some was due to cavitation. The signal from cavitation faded away in a few seconds after the exposure.




Figure 1. Typical B-mode and Doppler display during histotripsy exposure of pork muscle tissue showing the Doppler signal at the focal point (centre of tissue) as well as a previous HIFU lesion on the left side of the tissue. There are cm markers on the left side. The therapy beam comes from the bottom of the image. The insert shows the coaxial transducers.

When delivering histotripsy, the coaxial transducer running in power Doppler mode showed the location of the focal spot during the exposure, likely due to the motion of tissue

and cavitation bubbles (Fig. 1). It was not possible to see a lesion after a single histotripsy exposure.

3.2 Acoustic Camera

Figure 2 shows the image of a typical HIFU lesion. Although the HIFU lesions were usually detectable using the acoustic camera, it was rarely possible to find a single histotripsy lesion with this technique.

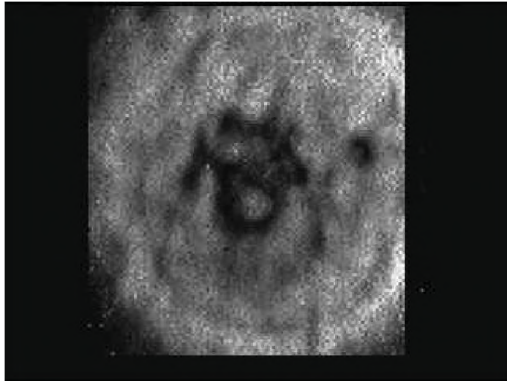


Figure 2. Acoustic Camera image of a HIFU lesion in the pork muscle tissue. The image is 2.4 cm wide \times 2.6 cm high. The therapy beam is perpendicular to the image.

3.3 Opto-acoustic Imaging System

The Imagio® opto-acoustic imaging system combines the advantages of optical and ultrasound imaging. The laser-induced ultrasonic waves in tissues are generated by the thermoelastic expansion of optical absorbers, allowing ultrasonic detection of millimeter-sized optical inhomogeneities (Fig. 3).




Figure 3. Opto-Acoustic image of four lesions in different depths in pork muscle tissue. A and B are HIFU lesions : C and D are histotripsy lesions.

3.4 Physical examination of tissue.

After employing all imaging techniques, the tissue was cut open and photographed. HIFU lesions were easily observed

(Fig. 4.), but it was never possible to see a single histotripsy lesion.

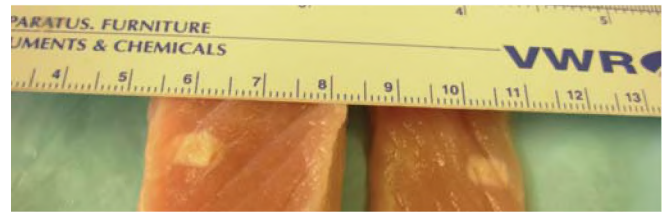


Figure 4. Treated tissue cut and folded open, showing HIFU lesion in its middle, not visible before slicing tissue. The therapy beam axis was horizontal in this photo.

4. DISCUSSION

Two different high intensity ultrasound lesions were formed and three modalities adopted in assessing the lesions. HIFU lesions were clearly shown in both B- and power Doppler modes by the coaxial imaging transducer; both during and post exposure. The same transducer, in power Doppler mode, clearly shows where the histotripsy lesions are being formed during exposure. A single histotripsy lesion is not visible post exposure due to its small size. The AcoustoCam® sometimes showed the HIFU lesions and sometime did not. Occasionally, a histotripsy lesion could be seen with this device. In transmission imaging, the signals through the entire depth of the sample are superimposed at the detector, eliminating the ability to distinguish between small volumes with little difference in signal. An Opto-Acoustic imaging system gave clear images of HIFU lesions and occasionally a poor image of a histotripsy lesion. An array of histotripsy lesions was necessary to create a lesion that was large enough to be seen reliably on any of the imaging systems. After all imaging techniques had been employed, the phantoms and tissues were cut open and the lesions photographed. More work is on progress to increase the sensitivity and specificity of the imaging methods to detect and to image histotripsy lesions.

REFERENCES

- Bailey et al., "Physical mechanisms of therapeutic effect of ultrasound", *Acoustical Physics*, Vol. 49, No. 4, 2003, pp. 437–464
- Winterroth, et al., "Tissue Fragmentation by Pulsed Cavitation Ultrasound-Histotripsy", *IEEE Int.Ultrasonics Symposium*, New York, 2007
- Oraevsky et al., "Optoacoustic imaging of blood for visualization and diagnostics of breast cancer", *Biomedical Optoacoustics III*, *Proceedings of SPIE Vol 4618*, 2002

ACKNOWLEDGEMENTS

This work was partially supported by grants from NSERC, /CIHR, Health Research Project 323745-06, and Ontario Research Fund ORF-RE. We thank Ultrasonix Medical Inc. for technical support.