

# OPTICAL COHERENCE TOMOGRAPHY FOR CLINICAL OTOTOLOGY

Dan MacDougall<sup>\*1</sup>, Thomas Landry<sup>†1,2</sup>, Manohar Bance<sup>‡1,2</sup>, Jeremy Brown<sup>§1</sup>, and Robert Adamson<sup>¶1</sup>

<sup>1</sup>School of Biomedical Engineering, Dalhousie University, Halifax NS, Canada

<sup>2</sup>Department of Surgery, Dalhousie University, Halifax NS, Canada

## 1 Introduction

Pathology of the human middle ear (ME) remains a challenging diagnostic problem for clinical otologists. The ME, an air-filled cavity located medially to the tympanic membrane (TM) at the end of the external ear canal, contains the chain of millimeter-sized, bony ossicles (malleus, incus, stapes) that conduct sound energy to the inner ear. Pathology of the middle ear causes conductive hearing losses which can arise from a variety of disorders (e.g. otosclerotic fixation, trauma, cholesteatoma, otitis media, erosion), many of which can be treated surgically. However, the currently available suite of imaging and diagnostic tools usually requires exploratory surgery through removal of the TM and direct microscopy of the ME for confident diagnosis before a treatment solution is chosen.

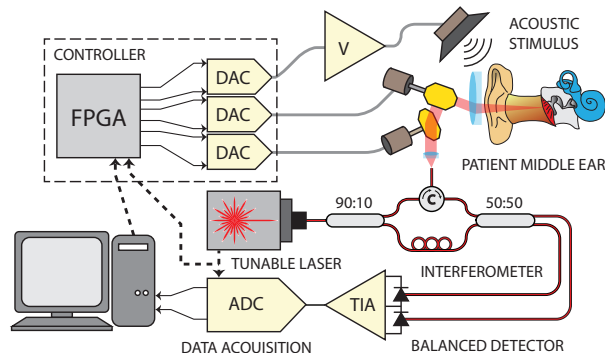
Optical Coherence Tomography (OCT) is an interferometric optical imaging technique that can be used to produce depth resolved images in biological samples [1] and can be thought of as the optical analog to ultrasonic imaging. By probing a tissue sample with a spatially coherent light source and interfering the back-scattered light with a reference beam, both the structure and dynamics of the sample can be inferred using a variety of interferometric techniques (i.e. phase-sensitive forms of time-domain OCT, spectral-domain OCT, swept-source OCT). Since the TM is thin ( $\approx 100\text{-}300\ \mu\text{m}$ ) and translucent, infrared light is able to penetrate it and allow non-invasive imaging of the middle ear with OCT. The potential for OCT in the middle ear has been previously recognized, for example in [2–4], but the technology has yet to be optimized for clinical use in otology where it could provide diagnostic capabilities unavailable with any existing tools.

## 2 Methods

### 2.1 SS-OCT engine design

We built a phase-sensitive swept-source OCT (SS-OCT) system and optimized it for real-time imaging of the human middle-ear, *in vivo*, with Doppler vibrometry capabilities. Our design is shown diagrammatically in Figure 1. Our infrared light source is an akinetically-tuned (i.e. no moving parts) swept-laser (SLE-101, Insight Photonics, 40 nm bandwidth centered at 1550 nm). A custom-built Mach-Zehnder fiber interferometer directs 90 % of the light to the sample where it is focused to a narrow beam, and recombines the collected backscatter with the remaining 10% for balanced detection. A custom, FPGA-based controller board was desi-

gned to synchronize all timing aspects of the system, including the control of two-axis scanning galvanometer mirrors and the generation of an acoustic frequency signal used to drive a speaker and excite the sample during acquisition.



**Figure 1:** Diagram of the swept-source OCT system designed and built for real-time clinical imaging of middle ear anatomy and function

In our system, the laser performs linear optical-frequency sweeps at a repetition rate of  $\approx 100\ \text{kHz}$ . The interference pattern generated during each sweep is sampled ( $\approx 400\ \text{MSPS}$  @ 12-bit resolution) and by the nature of SS-OCT, the sample’s reflection profile along the beam, called an A-line, is computed as its Discrete-Fourier-Transform (DFT). Structural 2D and 3D brightness-mode (B-Mode) images of the sample are generated from the magnitude of a number of A-lines. Simultaneously, since changes in position of a reflecting structure produce proportional phase shifts in its back-scattered light, sample dynamics along the beam path are extracted from the phase differences between consecutively acquired A-lines. In our system, by applying a pure-tone acoustic stimulus to the sample, the induced motions and resulting phase changes impart a frequency signature that is exploited to perform Doppler-Mode Vibrometry and extract functional information about the response of middle ear structure to sound stimulus using Fourier analysis.

In order to make the imaging engine suitable for clinical use, real-time processing, display and control were necessary. A graphical user interface (GUI) written in C++ using the Qt framework was developed to interface with the system hardware and manage patient data. Real-time signal processing of the interferometric data was implemented on a GPU with Nvidia’s parallel programming platform, CUDA, with cuFFT and several custom-written execution kernels that perform raw-data conditioning, windowing and dispersion compensation, B-Mode averaging, and Doppler-Mode calculations.

\*. dan.macdougall@dal.ca

†. tglandy@dal.ca

‡. m.bance@dal.ca

§. j.brown@dal.ca

¶. rob.adamson@dal.ca

## 2.2 Optimization for clinical use in patients

The clinical adoption of OCT into otology will be made easier if it can provide new diagnostic capabilities without disturbing the existing clinical workflow. In a modern clinic, typically a patient is asked to lie down while a surgical microscope is used to look down the ear canal for visible abnormalities. A speculum is used to straighten the natural curvature of the ear canal and gain line-of-sight to the TM and ME. Our OCT imaging system was designed to provide images without disrupting this workflow.

We outfitted an existing articulated surgical microscope mount with custom-designed OCT scanning optics using off-the-shelf parts. The scanner images through a rigidly mounted speculum of standard size with a 4.5 mm aperture. A field-of-view wide enough to accommodate the entire TM's width,  $\approx 10$  mm, is achieved by intentionally introducing fish-eye distortion to the optics' scan pattern.

The OCT engine described above was integrated into a mobile cart to operate the system alongside the articulated scanning head. The entire assembly is located in a dedicated testing room within the ENT clinic over a gurney for patients to lie on during examination.

## 3 Results

### 3.1 Preliminary imaging and validation

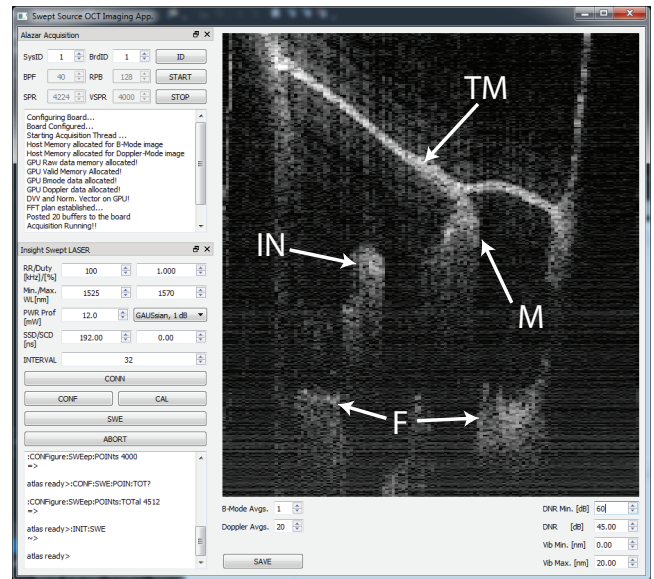
Figure 2 shows a screen capture from the GUI during real-time imaging (20 frames-per-second) in the clinic. The large field of view in both the lateral and depth directions ( $\approx 12$  mm x 10 mm on center, respectively) is a key feature that makes our system well-suited to the middle ear.

While the Doppler vibrographic imaging capabilities are still being integrated into the GUI as a user-friendly real-time diagnostic tool, we have previously confirmed our system's ability to measure nanometer-scale vibration of the ossicles in bench-top experiments using human cadaver specimens.

## 4 Discussion

Across the several design iterations and cadaver experiments leading to the current clinical system, the benefit of wide-field imaging became apparent. While excellent images are easily obtained using simple optics in cadaver specimens that have had the bony ear canal drilled away to expose the TM, the resulting limited field-of-view in intact ears makes the identification of anatomical structures and landmarks difficult. Our wide-field optics' ability to provide images of the entire middle ear simultaneously has met with favour from our clinical partners who have found operating the system on volunteers from within our research group to be very natural. We expect the technology to allow better decision making and surgical treatment planning, to provide better post-operative monitoring, and to improve the clinician's ability to recommend against surgery altogether where it is counterindicated.

We are currently in the process of training our clinical partners on the use of the system and ethics approval has been obtained to commence imaging on patient volunteers.



**Figure 2:** Screen capture from the real-time imaging GUI during *in vivo* imaging. The entire tympanic membrane (TM), the malleus handle (M), the end of the long process of the incus (I), and the floor of the middle ear (F) are all captured in the same image acquired down the intact ear canal

## 5 Conclusions

We have presented our novel phase-sensitive SS-OCT middle ear imaging system in its final design stages as we prepare to deploy it in clinical trials. We have also outlined the role OCT will likely play within the existing clinical workflow and where it is likely to impact middle ear diagnostics.

## Acknowledgments

We would like to thank Colibri Technologies for providing the computer cart used to house our system in-clinic and NSERC and ACOA for project funding.

## References

- [1] J.A. Izatt and M.A. Choma. *Optical Coherence Tomography Technology and Applications*, chapter Theory of Optical Coherence Tomography. Springer, 2008.
- [2] Pitris C, Saunders KT, Fujimoto JG, and Brezinski ME. High-resolution imaging of the middle ear with optical coherence tomography : A feasibility study. *Archives of Otolaryngology-Head & Neck Surgery*, 127(6) :637–642, 2001.
- [3] Ernest W Chang, Jeffrey T Cheng, Christof Röösl, James B Kobler, John J Rosowski, and Seok Hyun Yun. Simultaneous 3d imaging of sound-induced motions of the tympanic membrane and middle ear ossicles. *Hearing research*, 304 :49–56, 2013.
- [4] Hreesh M Subhash, Anh Nguyen-Huynh, Ruikang K Wang, Steven L Jacques, Niloy Choudhury, and Alfred L Nuttall. Feasibility of spectral-domain phase-sensitive optical coherence tomography for middle ear vibrometry. *Journal of biomedical optics*, 17(6) :0605051–0605053, 2012.